

# Freeze-dried chitosan-PRP implants can be injected into meniscus tears and improve repair in an ovine model

L Ghazi zadeh<sup>1</sup>, A Chevrier<sup>2</sup>, M Hurtig<sup>3</sup>, J Farr<sup>4</sup>, S Rodeo<sup>5</sup>, CD Hoemann<sup>1,2</sup> and MD Buschmann<sup>1,2</sup>

<sup>1</sup>Biomedical Engineering Institute and <sup>2</sup>Chemical Engineering Department, Polytechnique Montreal, Montreal, QC, Canada, <sup>3</sup>Department of clinical studies, University of Guelph, Guelph, ON, Canada, <sup>4</sup>OrthoIndy Knee Care Institute and Cartilage Restoration Center of Indiana, Greenwood, IN USA, <sup>5</sup> Orthopaedic Surgery, The Hospital for Special Surgery, New York, NY, USA

**Disclosures:** AC, MH, CDH and MDB are shareholders, JF and SR are clinical advisors and CDH and MDB are Directors of Ortho Regenerative Technologies Inc.

**INTRODUCTION:** Meniscal tears are among the most common knee injuries. Surgical treatment of symptomatic meniscal tears often involves partial removal of torn meniscus, which increases the patient’s risk of developing osteoarthritis. Lesions in the vascular region of the meniscus have high potential for repair while healing is more limited in the avascular portion of the meniscus. Therefore, tears that are further away from the periphery could benefit from different augmentation modalities. Trephination as an augmentation technique has had limited success in pre-clinical models (1) and in clinical studies (2), and lack of cell recruitment and neo-vascularization are thought to be the primary reasons for this failure. The meniscus wrapping technique was developed in order to augment the rate of healing for complex tears (3). We have developed freeze-dried chitosan (CS) formulations that can be solubilized in platelet-rich plasma (PRP) to form injectable implants that coagulate *in situ*. These implants have been shown to induce vascularization and cell recruitment *in vivo* in the context of meniscus repair (4). In the current study, we combined the meniscus wrapping technique and the application of CS-PRP implants in a unilateral complex tear model in the sheep meniscus. The purpose of this study was to investigate whether healing of ovine meniscus tears can be augmented by applying chitosan-PRP implants and wrapping the meniscus with a collagen membrane.

**METHODS:** Canadian Council on Animal Care guidelines were observed and institutional review board approval was obtained. Formulations containing 1% (w/v) chitosan (80.2% DDA and  $M_n$  36 kDa), 1% (w/v) trehalose (as lyoprotectant) and 42.2 mM calcium chloride (as clot activator) were freeze dried and solubilized in autologous PRP immediately prior to application. 10 mm longitudinal tears with a horizontal component were created unilaterally in the medial meniscus of six mature ewes and treated by suturing and either injecting chitosan-PRP in the tear (n=2), wrapping the meniscus with a collagen membrane and injecting chitosan-PRP in the tear and under the wrap (n=2) or wrapping only (n=2). Repair was assessed histologically at 6 weeks.

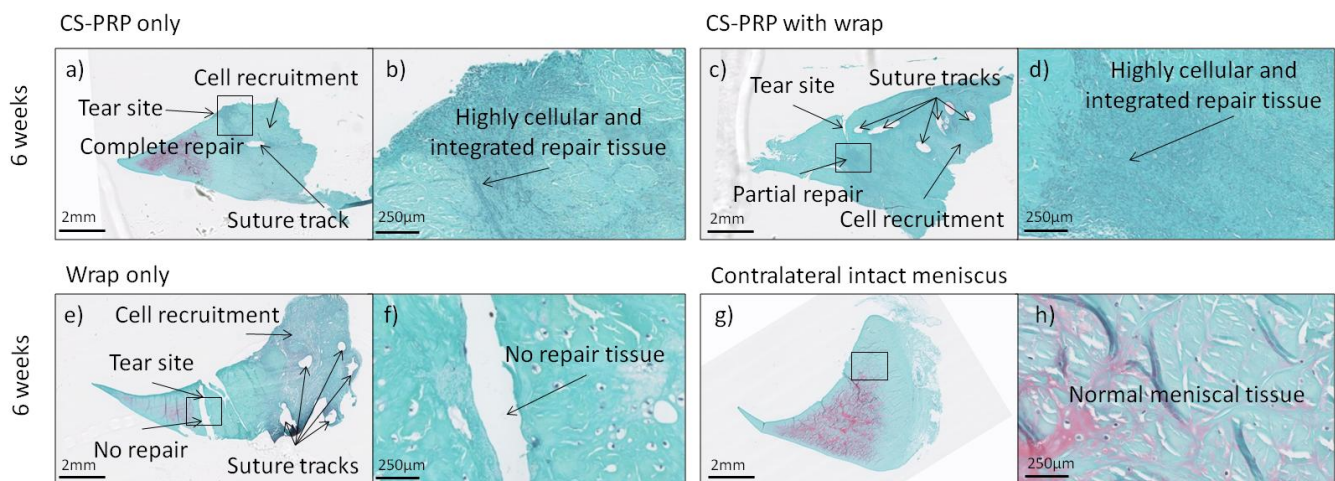
**RESULTS:** Complete healing and seamless integration were observed in one chitosan-PRP treated tear (Fig 1 a&b), while there was partial healing in one tear treated with chitosan-PRP and wrapping (Fig 1 c&d). The repair tissue was highly cellular and well integrated to surrounding host meniscus (Fig 1 a to d), but structurally different than intact contralateral menisci (Fig 1 g&h). There was no healing in the menisci treated with wrapping alone (Fig 1e&f). Significant cell infiltration was observed at the outer portion of all treated menisci compared to intact contralateral menisci (Fig 1 a, c & e vs g). Suture tracks were abundant in menisci treated with the wrapping technique (Fig 1 c&e).

**DISCUSSION:** Freeze-dried chitosan formulations can be rapidly solubilized in autologous PRP to form injectable *in situ* solidifying implants that have tissue regeneration capacity. Chitosan-PRP implants showed superior regenerative effect over wrapping the meniscus with a collagen membrane. Using the wrap in conjunction with chitosan-PRP implants did not further improve repair and the additional sutures needed to secure the wrap created significant damage to the menisci. This suggests that chitosan-PRP implants by themselves could be effective in overcoming the current limitations of meniscus repair. The different treatments did not induce any deleterious effect on the other joint components aside from a mild-to-moderate synovitis at 6 weeks (not shown), which is expected to resolve with time. This study had some limitations, including the small number of animals assessed in each group and the short repair period. The complex tear was also more challenging than a simple longitudinal tear but may be more representative of the clinical situation where successful treatment of complex tears is difficult, in comparison to vertical tears that can be more readily sutured with some potential for healing. Finally, although sheep are a convenient large-animal model for biomedical research due to availability, similarity to human joints, ease of handling and post-op joint loading in quadrupeds are quite different than humans.

**SIGNIFICANCE:** Chitosan-PRP implants showed superior regenerative effect over wrapping the meniscus with a collagen membrane. Chitosan-PRP implants have several features that reveal their potential to improve repair outcomes and restore meniscus function.

**REFERENCES:** 1) Zhang et al 1995, Am J Sports Med, 23, 1: 35-41; 2) Zhang et al 1996, Arthroscopy, 12, 6: 726-731; 3) Piontek et al 2016, Cartilage, 7, 2: 123-139; 4) Chevrier et al 2016, Transactions ORS 2016.

**ACKNOWLEDGEMENTS:** We acknowledge the technical contributions of Geneviève Picard, Sothead Sim and the funding sources (CIHR, CFI, GRSTB, NSERC and Ortho Regenerative Technologies Inc).



**Figure 1.** Safranin O/Fast Green-stained coronal sections of menisci were used to evaluate tissue repair after 6 weeks. One tear treated with chitosan-PRP only showed complete repair (a, b), while one tear treated with chitosan-PRP with wrapping was partially healed (c, d). There was no repair tissue in the group treated with wrapping only (e, f). In the two cases where repair was observed (a to d), the repair tissue was highly cellular, well integrated to the adjacent meniscal tissue, but structurally different than the intact contralateral menisci (g, h). Significant cell recruitment to the outer portion of all treated menisci was observed (a, c & e) compared to intact contralateral menisci (g). Suture tracks were frequently observed in menisci treated with the wrapping technique (c & e). Rectangles in panels a, c, e & g demonstrate regions where the higher magnification images b, d, f & h were acquired.